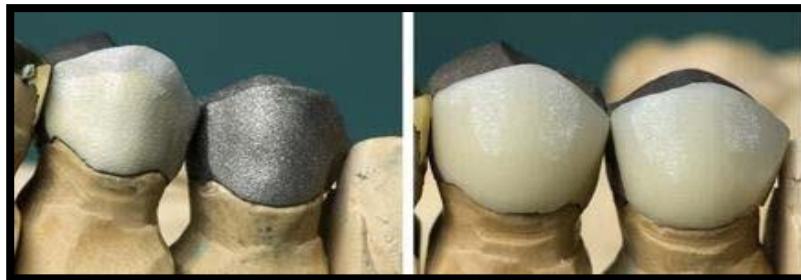
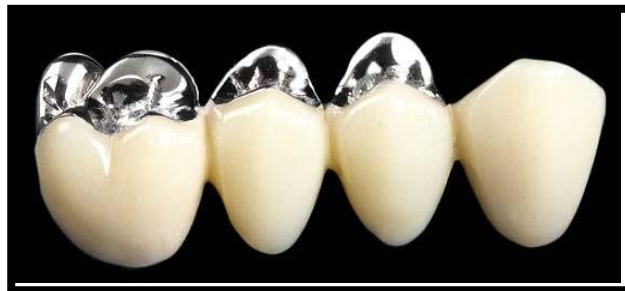

Porcelain Fused to Metal Crown

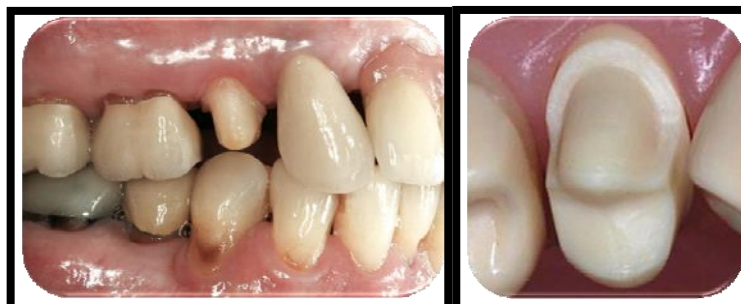Porcelain fused to metal (PFM) crown is the most widely used fixed restoration. It is a full metal crown having a facial surface (or all surfaces) covered by ceramic material. It consists of a ceramic layer bonded to a thin cast metal coping. It combines the strength and accurate fit of cast metal coping with the cosmetic of ceramic.



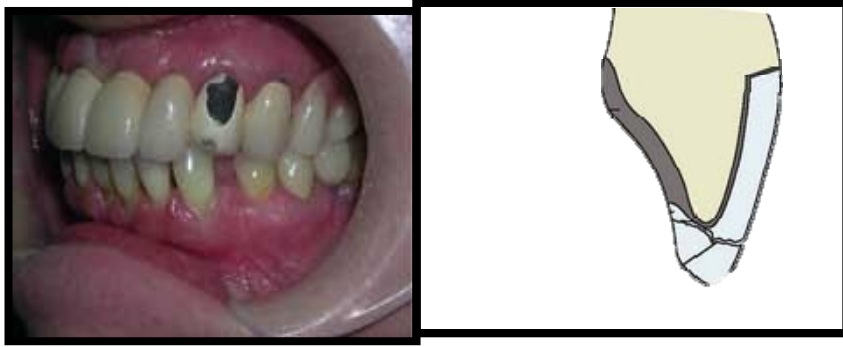So, this type combines the advantages of the strength of full metal crown and esthetic of all ceramic crown.

Disadvantages of PFM crown

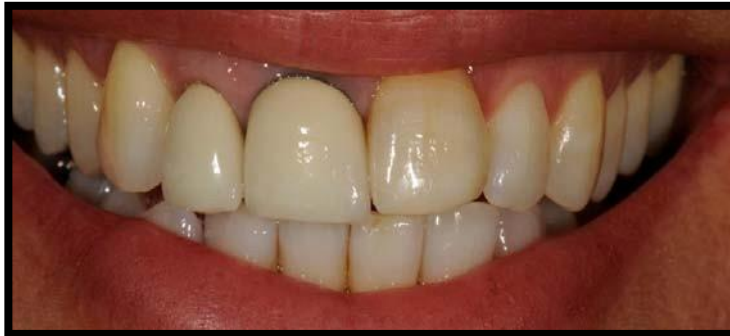1. Removal of substantial amount of tooth structure.



-
2. Subject to fracture because of the brittle nature of porcelain.



3. Shade selection can be difficult.
4. Inferior esthetic compared to porcelain jacket crown.
5. Discoloration of the gingival margin may occur with time.
6. More expensive.



Indications of PFM crown

1. Teeth need to be completely covered for esthetic demand.
2. As a retainer for fixed partial denture.
3. Similar to those of full metal crown.

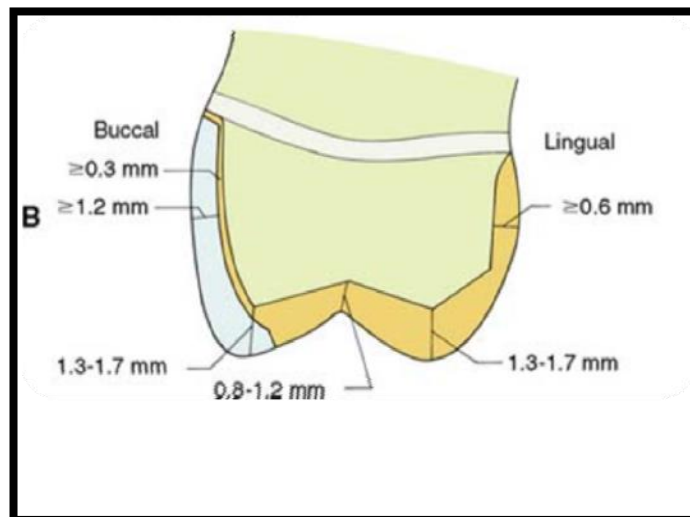
Contra-indications of PFM crown

1. Teeth with large pulp (because of the possibility of pulp exposure during preparation).
2. Intact buccal wall where a more conservative retainer can be used.
3. Teeth with short crowns.
4. Patient with bad oral hygiene.

Preparation Requirements:

- Deep facial reduction to provide enough space for the metal coping and porcelain and shallower reduction on the other surfaces covered with metal only.
- Shoulder, radial shoulder, or heavy chamfer can be used as a gingivo-facial finishing line, whereas chamfer or knife edge finishing line is used for the remaining surfaces covered with metal only.

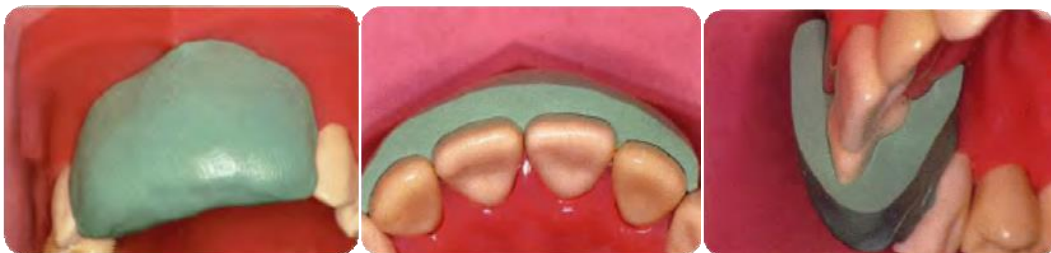Since this restoration is a combination of metal & porcelain, tooth preparation likewise is a combination.



Tooth preparation of PFM crown (for anterior teeth)

Fabrication of silicone index

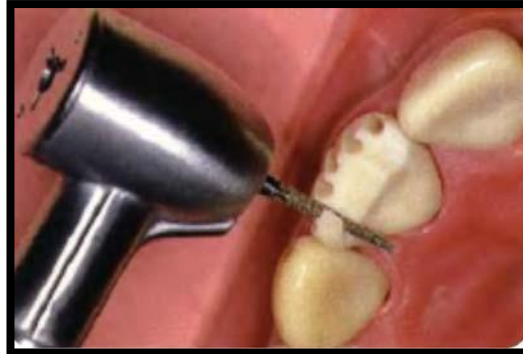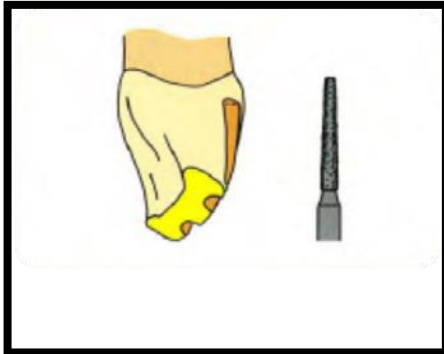
The silicone index acts as a guide to check the amount of tooth structure removal.



Incisal reduction

2 mm should be removed from the incisal edge to allow for adequate translucency of the restoration.

Flat-end tapered diamond bur is used, placed parallel to the incisal inclination (with a slight palatal inclination in the upper incisors and labial inclination in the lower incisors).

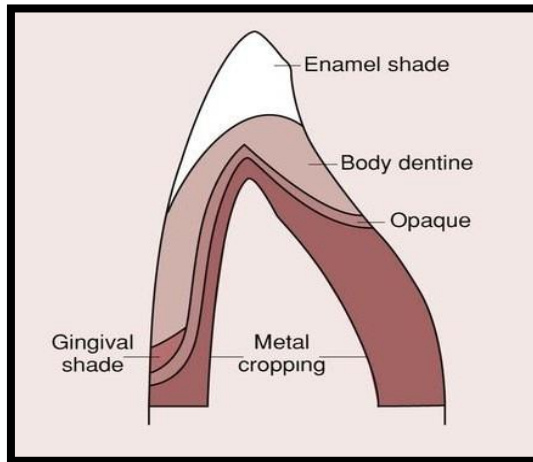


Labial reduction

PFM crown preparation requires deep facial reduction to give enough space for metal and porcelain, and thus avoiding over contouring and poor esthetic which would inevitably occur when no enough tooth structure is removed. The amount of labial reduction is 1.5-2 mm.

Advantages of adequate reduction (deep facial reduction)

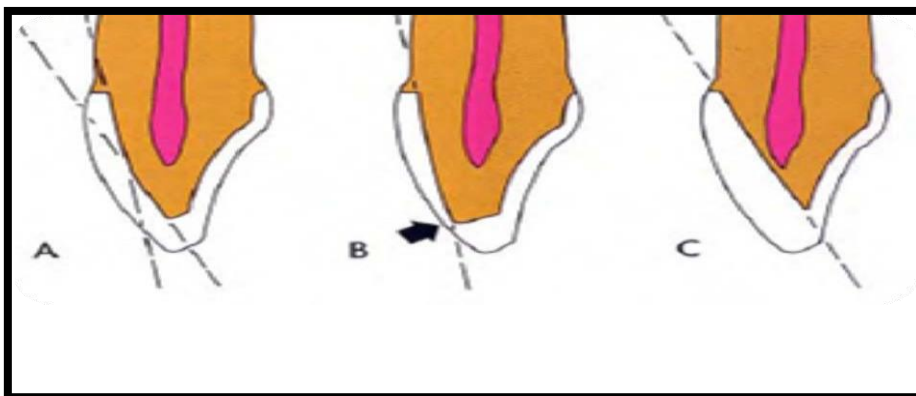
1. The restoration will properly contour (effect on esthetic & gingival health).
 2. The shade & translucency of the restoration will match that of the adjacent natural tooth.
- 0.5 mm for the metal coping.
 - 1 mm for porcelain (0.2 mm opaque layer, 0.5 mm body “dentin” layer, and 0.3 mm incisal “enamel” layer).



Because of the anatomy of the tooth labially, it should be reduced in two planes corresponding to the two geometric planes of the labial surface: a gingival plane and an incisal plane.

Advantages of two plane reduction

1. To follow the anatomy of the surface.
2. To avoid hitting the pulp.
3. To give enough space for the metal and porcelain layers, so that avoiding poor esthetic or over contour.



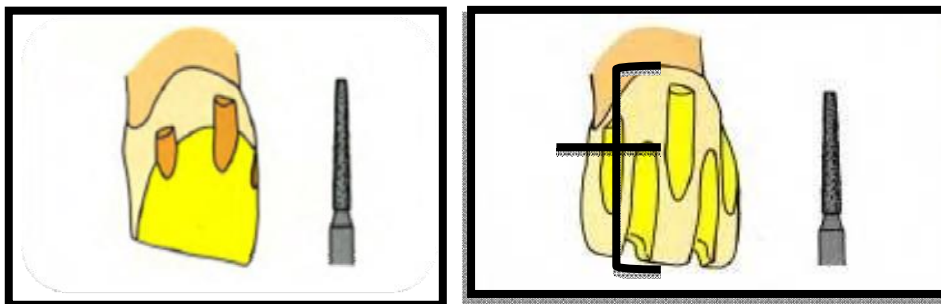
a. Gingival plane

Three D.O.G (1.5 mm in depth) are placed in the gingival third of the labial surface parallel to the long axis of the tooth.

b. Incisal plane

Three D.O.G (1.5 mm in depth) are prepared parallel to the inclination of this area.

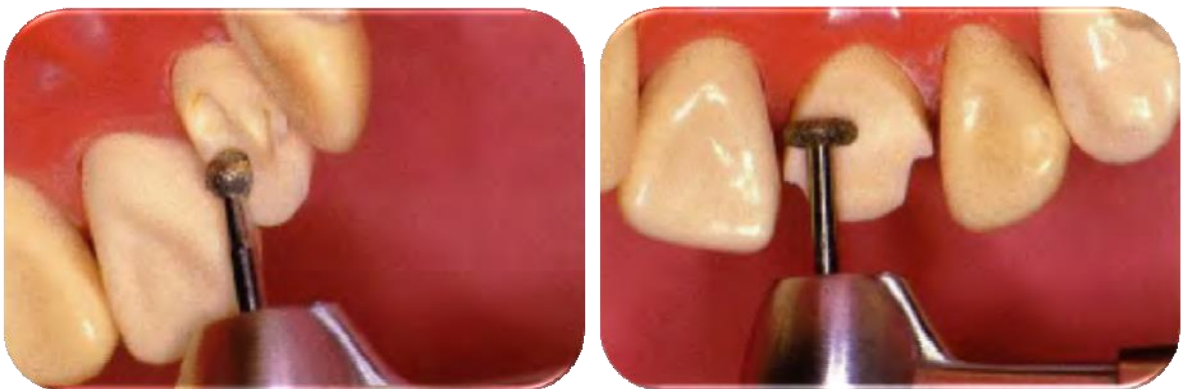Flat-end tapered fissure bur is used to create a shoulder finishing line extended 1mm lingual to the contact.



Palatal (lingual) reduction

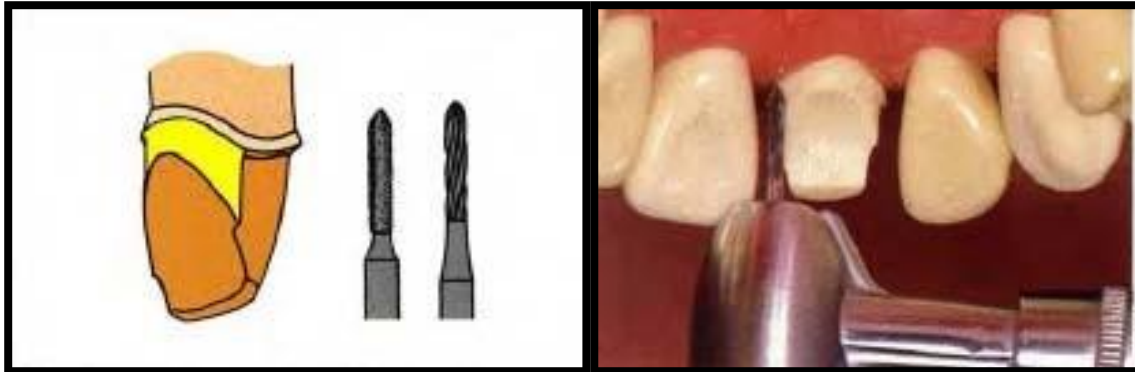
a. Cingulum area reduction

D.O.G. of 1mm in depth is placed in the center using a round bur 1 mm in diameter. A small wheel diamond bur is then used to reduce this area following the concavity of this part of tooth surface.




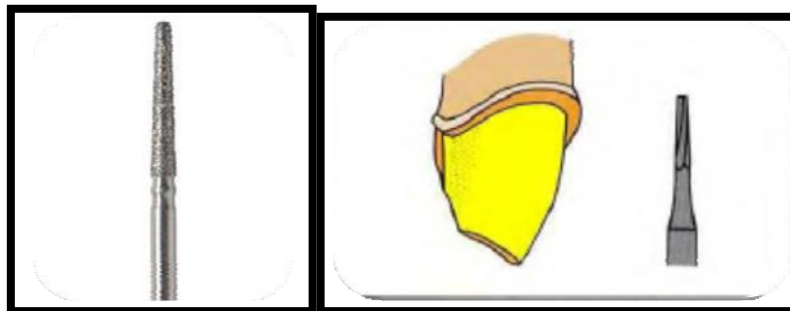
b. Lingual axial reduction

D.O.G. of 1mm in depth is placed parallel to the long axis of the tooth. A round- end tapered fissure bur is then used to reduce this area parallel to the long axis of the tooth to create chamfer finishing line.

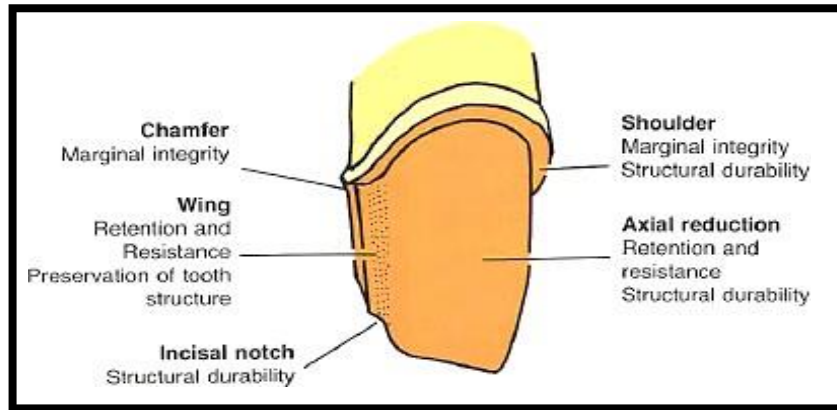


Proximal reduction

A pointed tapered fissure bur (long needle) is used to break the contact with the adjacent tooth, moving the bur up and down from the palatal to the labial. A round-end tapered fissure bur is then used to create a chamfer finishing line continuous with the chamfer finishing line of the palatal surface and joining the shoulder finishing line of the labial surface at a line angle called "wing".



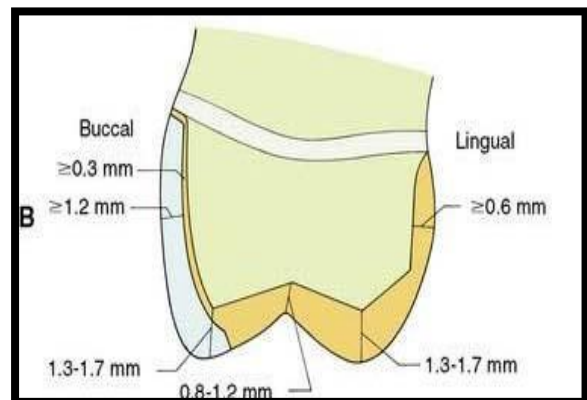
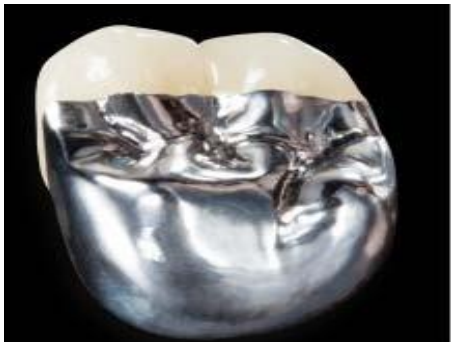Checking of the amount of tooth reduction using the silicone index.



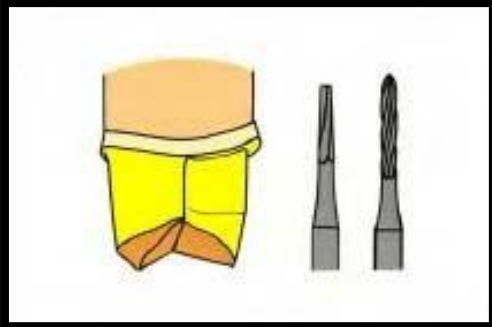
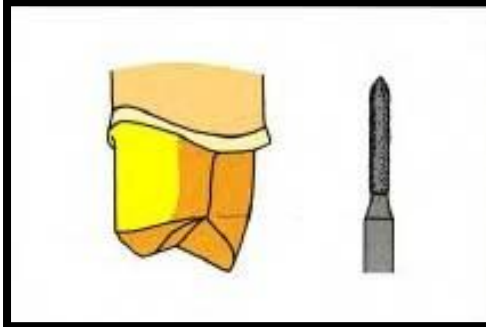
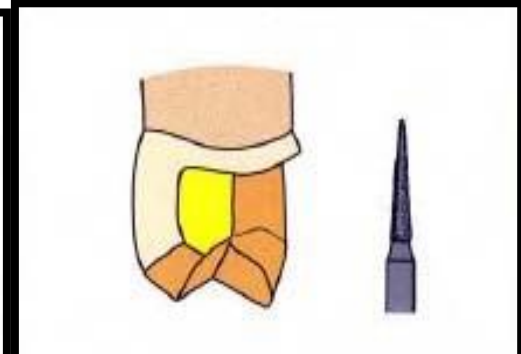
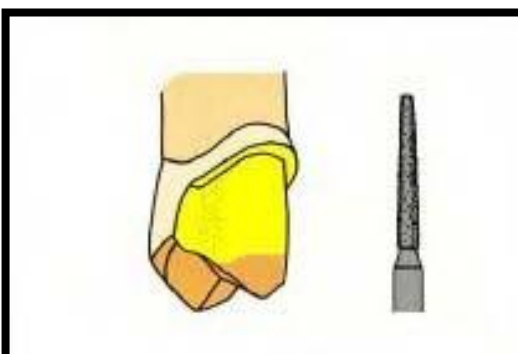
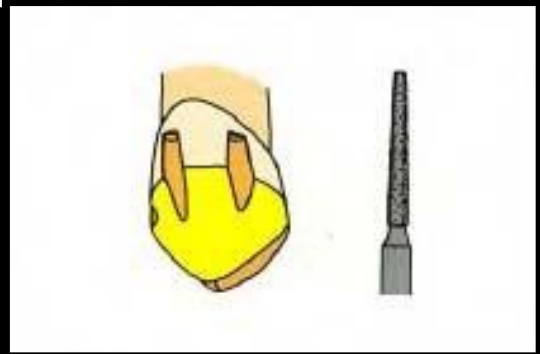
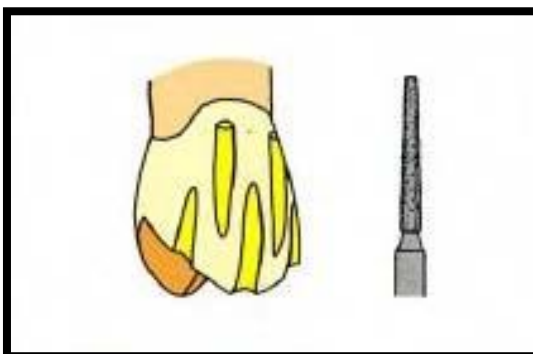
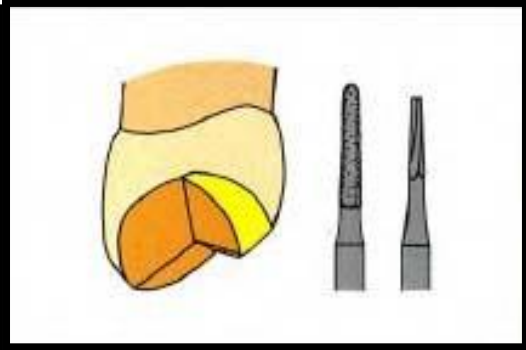
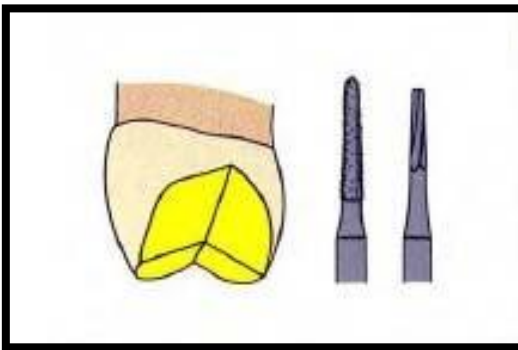
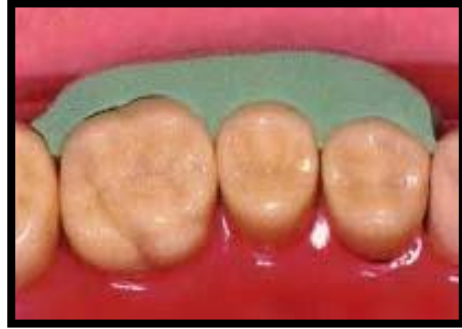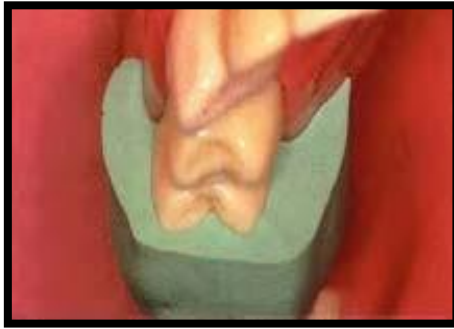Tooth preparation of PFM crown for posterior teeth

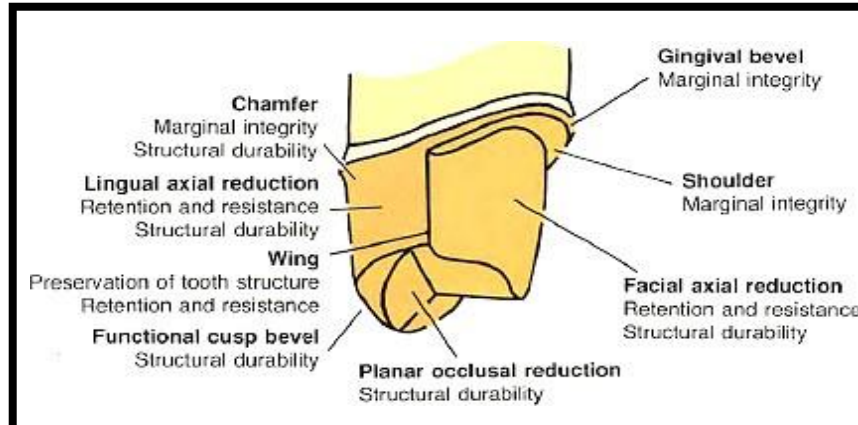
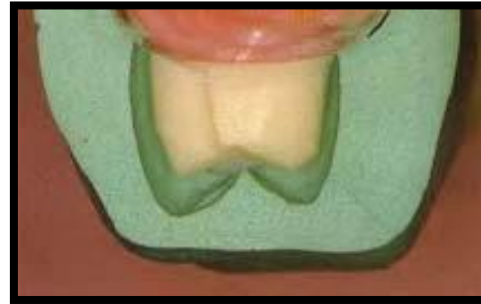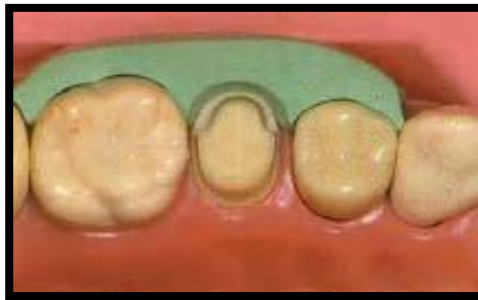The same principles of full metal crown preparation are used with exception of providing a deep reduction in the area that is to be covered with both metal and porcelain.

- 1.5 mm for the non-functional cusps.
- 2 mm for the functional cusps.
- 1.5-2 mm for the facial reduction.



The same steps of PFM crown preparation for the anterior teeth are used for the posterior teeth starting with fabrication of a silicone index.





Full metal crown with acrylic facing

- It is a full metal crown whose labial or buccal surface is covered with tooth-colored acrylic resin. It has been widely used previously before the use of porcelain as a facing material, but still used nowadays due to its lower cost as compared to PFM.
- It combines the strength and accuracy of full metal crown with the esthetics of tooth-colored acrylic resin.
- It is less expensive than PFM crown.
- The preparation involves deep facial reduction to provide enough space for both metal and facing material.
- The finishing line is shoulder with bevel facially (labially or buccally) and chamfer or knife edge for the other surfaces. When esthetic is critical, sub-gingival positioning of the finish line is recommended.

The main disadvantages of this type of crown are related to the acrylic facing material, including discoloration with time, wearing, and poor compatibility of the acrylic resin with the gingival tissue.

